

A real pain in the neck: Cervical artery dissection

Check out our other handouts and podcasts at www.emboardbombs.com

Twitter/Instagram: @emboardbombs



Board Bombs

Author: Blake Briggs, MD

Peer Reviewer: Travis Smith, DO

Introduction

Cervical artery dissections are a common cause of stroke in young people <50 years old with some reports of up to 20% being from dissections. They can occur at any age. Much like aortic dissections, there is some loss of structure along the wall of either the internal carotid artery (ICA) or vertebral artery (VA), allowing blood to collect within the intima. This review will focus on spontaneous dissections, not traumatic, as well as the pathophysiology, risk factors, presentation, diagnosis, and management.

In patients <50 years old, cervical artery dissections account for 20% of ischemic strokes. The overall incidence is about 2.5 per 100,000 annually in the US alone, with a mean age of 45 years. ICA dissections are 3-5x more common than VA dissections. For comparison, subarachnoid hemorrhage (SAH), another can't-miss neurological diagnosis, has an incidence of ~7 per 100,000 worldwide.

Pathophysiology

As stated above, a separation of the arterial wall layers results in dissection. They occur extracranial or intracranial. Extracranial dissections are more common with the internal carotid artery 2 cm distal from the carotid bifurcation and the V3 segment of the vertebral artery at the C1-C2 level are the most common locations.

The false lumen that forms will continue to dissect, or "unzip", resulting in cerebral ischemia. Ischemia is caused by both hypoperfusion or thromboembolism, with the latter being more important. The compression of the expanding hematoma presses on sympathetic fibers on the outside of the blood vessel and adjacent nerves, resulting in Horner syndrome (see below), cranial neuropathies, and pain. Very rarely do these vessels dissect intracranially, rupturing to cause a SAH.

Risk Factors

Minor trauma: the key word is "mild" trauma, associated with up to 40% of cases. This does not include motor vehicle crashes that end up at a level 1 trauma center with a cervical spine fracture. These are usually activity related: skating, basketball, volleyball, swimming, scuba diving, dancing, yoga, chiropractors (1 in 20,000 cervical manipulations), sexual intercourse, trampoline use, amusement park rides, vaginal delivery, etc.

With that being said, most CADs develop in the absence of any discernible mechanical event thus making it very difficult to indict a particular incident or factor as the cause of a particular stroke.

The most compelling risk factors have likely have to do with an underlying connective tissue abnormality, which likely contribute to a weakening of the vascular wall. These genetic predispositions are the usual culprits (Ehlers-Danlos, Marfan's, PCKD, etc). The most common of these is fibromuscular dysplasia.

While both vertebral and cervical dissections are associated with minor trauma, vertebral dissection has a higher rate and they are especially more associated with rapid head movements.

Presentation

Think headache, neck pain, and potentially ischemic, neurologic symptoms.

It is important to add this pathology to your differential of patients with headache and neck pain in the absence of trauma as headache and neck pain are the most common symptoms, ranging from 60-90%. Headache is more common in carotid dissections, while neck pain is more common in vertebral dissection. See image 1 for the common associated pain locations.

The headache onset is usually gradual, with <20% being a "thunderclap" onset. Both vertebral and carotid dissections have no difference in terms of occurrence and frequency of headache as a presenting symptom, as well as thromboembolism or mural thrombus hematoma.

Ischemia manifesting in TIA/stroke symptoms are present in about 70% of patients but this may not be present on initial presentation. The risk being highest during the first 2 weeks of symptoms (77% present at the time of diagnosis).

On exam, look for the obvious motor or sensory deficits in addition to the more subtle nystagmus, truncal ataxia (can't sit up in bed), ipsilateral horner's syndrome, tongue deviation, or an ophthalmoplegia

For vertebral dissections think of lateral medullary syndromes (Wallenberg Syndrome) and cerebellar infarctions and think amaurosis for carotid artery dissection.

As mentioned above, Ipsilateral Horner syndrome is only in ~25% of cases. Even so, it is usually partial, with only unilateral ptosis and miosis. Anhidrosis is rarely seen. Other possible symptoms include unilateral hearing loss, tinnitus, auscultated bruit, dizziness, the **Deadly D's** (dysarthria, diplopia, dysphagia), other cranial neuropathies, and scalp tenderness.

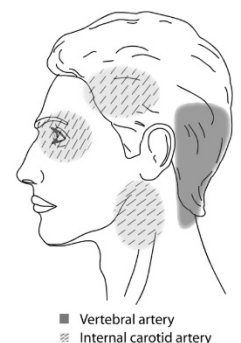


Image 1

Diagnosis

Made by neuroimaging, MRA or CTA. Both are more or less equal in performance and sensitivity/specificity. CTA is faster and has wider availability in most EDs. Historically, the gold standard was digital subtraction angiography, but this is rarely used today. Ultrasound can be used but its limitations include intracranial extension, imaging of the vertebral artery system, and the fact that it has been found to show evidence specific to dissection in only 20% of patients making it an imaging modality to forego.

Key findings on imaging: vessel stenosis, tapered occlusion, dissecting aneurysm (pseudoaneurysm), intimal flap, double lumen, or intramural hematoma.

Rarely, CTA and MRA can be falsely negative. If you have a strong suspicion for cervical artery dissection, proceed with arranging digital subtraction angiography.

Treatment

As discussed above, cervical artery dissection increases the risk of thromboembolism, causing stroke. This can be a deadly diagnosis as there is up to a 10% mortality prior to even initiating treatment.

In those patients who present with acute ischemic stroke, standard approaches to management of stroke should be followed. Discussion of thrombolytics should be held.

There is no increased harm in giving IV thrombolytics, but no clear benefit as well (i.e. no difference in intracranial hemorrhage, mortality, or favorable outcome).

One critical caveat is that thrombolytics are relatively contraindicated in those with intracranial extension of the dissection. Another complication that is quite obvious: a cervical artery dissection involving the aorta...we'll let you think about why that would be bad.

Anti-thrombotic therapy with either antiplatelet agents or anticoagulation are the preferred methods for preventing ischemic stroke and TIA complications. They have been studied and there is no difference in their efficacy.

There is debate on the preferred antiplatelet agents: aspirin, clopidogrel, dipyridamole, or a combination of these agents.

There is no consensus on how long patients need to be on therapy. Some studies suggest after 3-6 months as most arterial abnormalities stabilize by then. Repeat imaging is necessary at that time to evaluate for improvement in the dissection complications.

Endovascular or surgical repair are last resort options in those who have recurrent ischemia or failed antithrombotic therapy.

Prognosis

Recurrence rate is uncertain, and hotly debated. We do know that unfavorable outcomes are more common in carotid artery dissections versus vertebral. Excellent recovery has been found in 70-85% of patients, with major disabling deficits in 10-25% and death in <10%.

References

See our website page under the heading of this handout for complete reference list.

Please add these:

Haneline MT, Rosner AL. The etiology of cervical artery dissection. *J Chiropr Med.* 2007;6(3):110-120. doi:10.1016/j.jcme.2007.04.007

Britt TB, Agarwal S. Vertebral Artery Dissection. [Updated 2020 Jul 21]. In: StatPearls [Internet]. Treasure Island (FL): StatPearls Publishing; 2020 Jan-. Available from: <https://www.ncbi.nlm.nih.gov/books/NBK441827/>